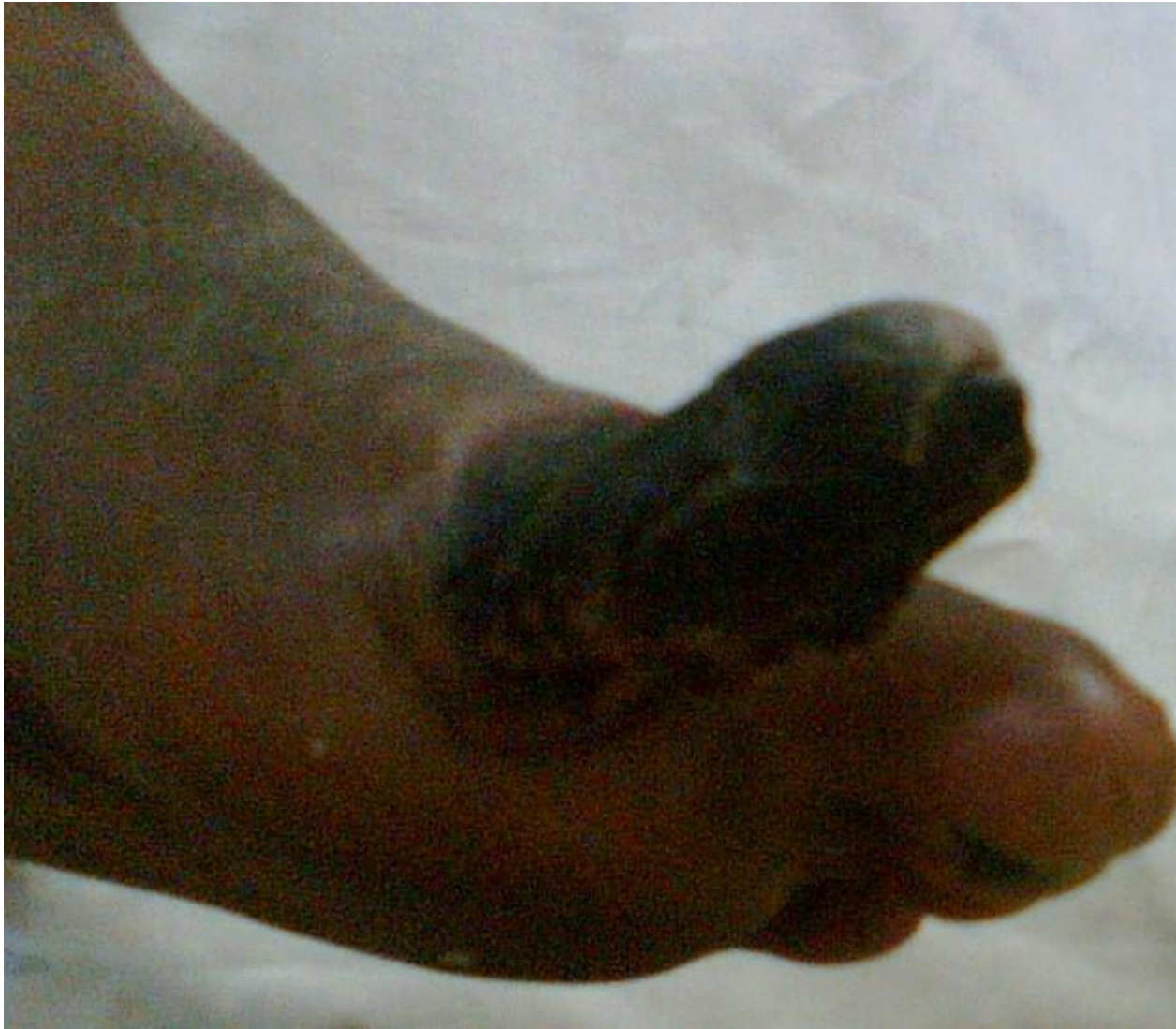

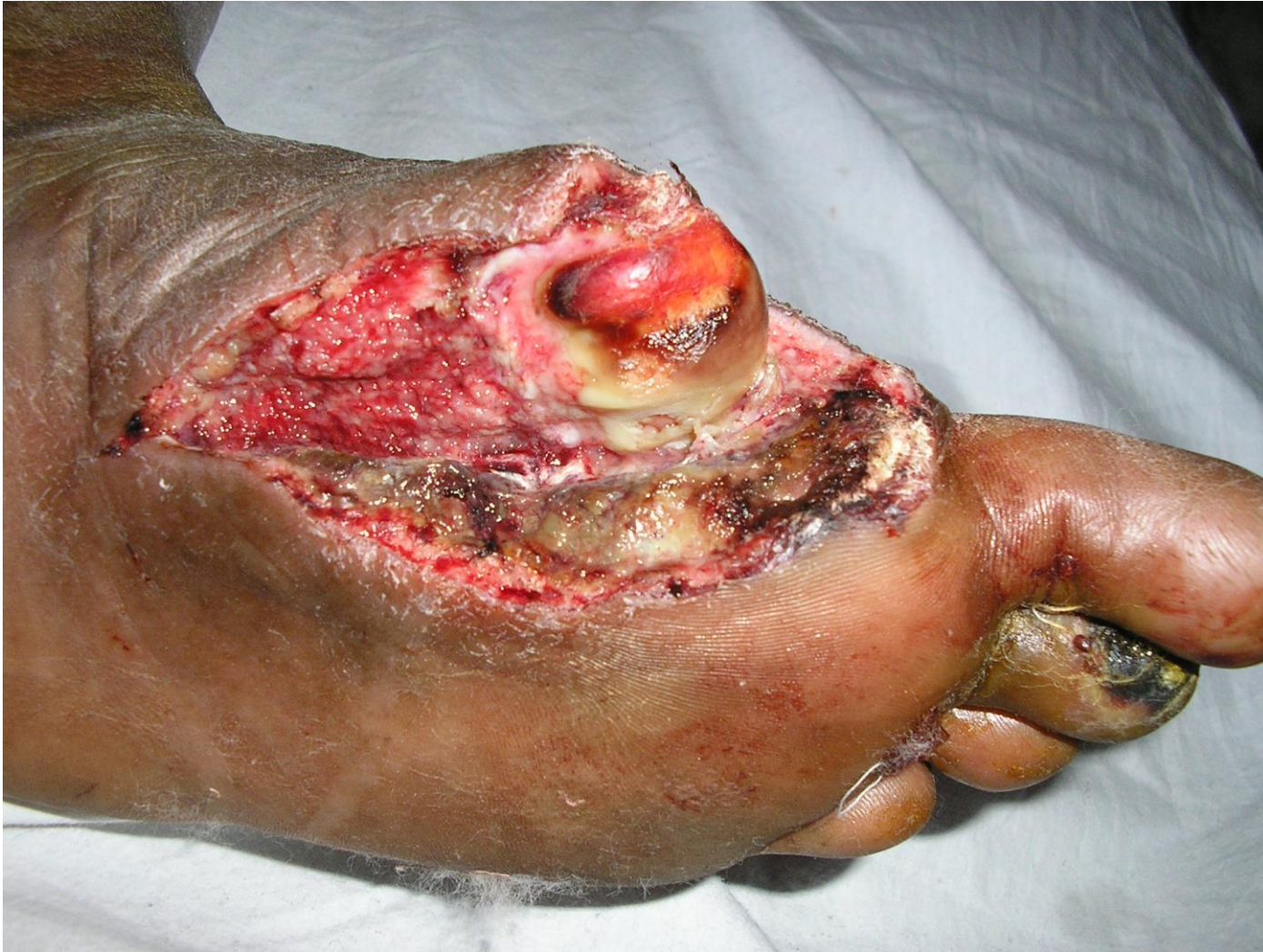Savelegs.com

Case of Known Diabetic with Gangrene of the first toe
with incipient gangrene of the 3rd toe.
Patient had peripheral arterial disease.



At presentation patient had gangrene of the first toe, gangrenous changes at the tip of the third toe & was in sepsis.

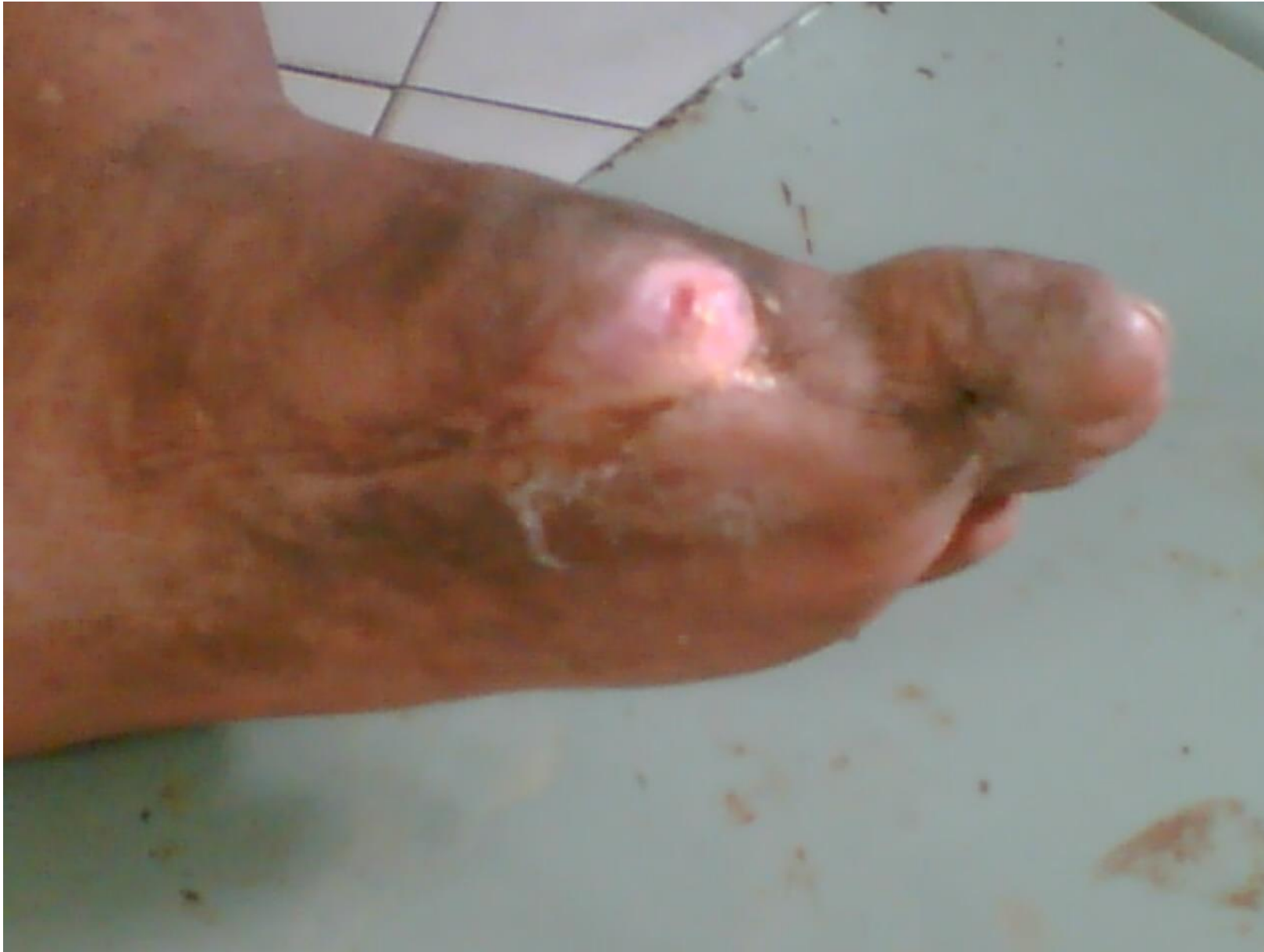Other than diabetes, he had no other co morbidities.



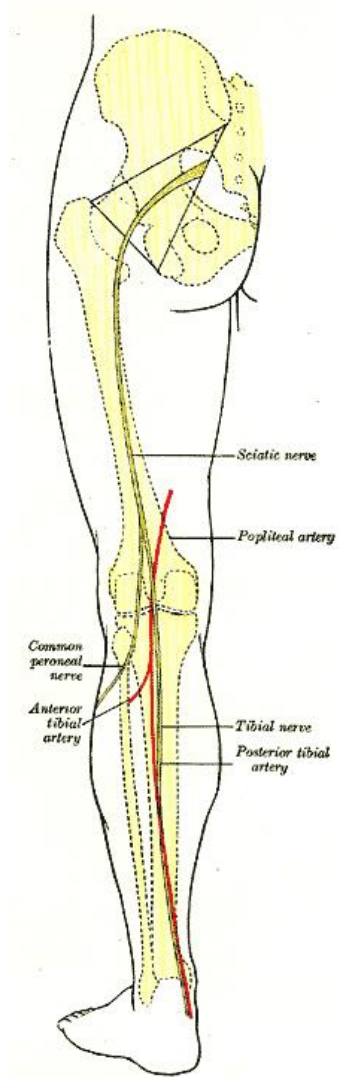
Exploration of the medial plantar space, disarticulation of the first toe at the meta tarso phalangeal joint and release of the POSTERIOR TIBIAL ARTERY at the ankle were carried out

Supportive treatment in the form of :

- Antibiotics as per C/S reports
- Blood sugar controls
- Rheologic agents
- Local wound care



Reversal of the Gangrenous changes to the third toe, Salvage of the foot and prevention of further gangrenous changes took place.



In my experience, release of the POSTERIOR TIBIAL ARTERY at the ankle in cases where there is mild to moderate disease in the lower limb vasculature with no discrete blocks, may be carried out to enable limb salvage to the benefit of the patient. Nowadays, I carry out PTA Release and supplement it with Hyper Baric Oxygen Therapy.